



Case Report

## ACUTE RETENTION OF URINE A RARE PRESENTATION OF TYPE 2 DIABETES MELLITUS (DM): CASE REPORT

Ather Pasha<sup>1\*</sup> and Suhail Bin Ahmed<sup>1</sup>

\*Corresponding Author: Ather Pasha ✉ [atharpasha@yahoo.com](mailto:atharpasha@yahoo.com)

Diabetes Mellitus is causing a big socioeconomic burden in developing countries. Inadequate education and awareness about disease and its complication has further added to existing scenario particularly in India. Common clinical features of Diabetes Mellitus include polyuria, polydipsia and weight loss, nonhealing skin infection. Here we report an unusual case of Diabetes Mellitus presenting as acute retention of urine due to prostatic abscess, which completely recovered with conservative treatment, highlighting complete evaluation, early diagnosis, treatment and prevention of complications.

Keywords: Diabetes Mellitus, Clinical Examination, Prostatic Abscess, Trans Rectal Usg, Antibiotics, Insulin

### INTRODUCTION

Diabetes Mellitus Type 2 is a common metabolic disorder characterized by hyperglycemia due to progressive beta cell failure, insulin resistance and increased hepatic glucose production leading to acute and long term chronic complications. According to WHO Estimate for year 2000, there were 171 million adults with diabetes in the world. In 2011 the International Diabetes Federation (IDF) set the figure at 366 million, this is predicted to rise to 552 million by 2030. The greatest increase is expected to be seen in India (~50 million) Hyderabad one of major cities in southern India is considered as capital

of Diabetes Mellitus in India.

### CASE REPORT

A 61 year male patient without significant past medical or surgical history presented with acute retention of urine with denovo hyperglycemia with *insitu* foley's catheter. He initially visited to a nearby local hospital for acute retention of urine where foleys catheterization was done for normal urine flow. His routine cell count, Blood chemistry and USG Abdomen were within normal limits. His blood sugar was found to be 296 mg/dL. He was treated symptomatic ally suspecting urosepsis with iv fluids, antibiotics (third Generation cephalosporins) and insulin for 3 to 4 days. Later foleys was removed and

<sup>1</sup> Department of Medicine, DCMS, Hyderabad.

was discharged on oral antibiotics and oral hypoglycemics.

Later same day by evening he again developed retention of urine and fever with chills and was henceforth referred to our hospital (Princess Esra Hospital) for further management. On examination, pulse was 100/min, and BP was 100/70 mmHg with postural hypotension. There was no Icterus, pallor, normal JVP with no pedal oedema. On examination of abdomen there was pain in suprapubic region and there was suprapubic dullness on percussion. Cardiovascular system examination was normal. Examination of chest was unremarkable.

Investigation revealed haemoglobin 13 g/dL, total white cell count 15,300/cm with raised neutrophil count. ESR 25 mm at 1 h, serum bilirubin 0.81 mg/dL, serum albumin 3.4 g/dL, SGPT 23 U/L, alkaline phosphatase 129 IU/L, PT 12 s with INR 1.00. The random plasma glucose level was 356 mg/dL. His HbA1c was 12.4%. Blood urea, sr. creatinine were normal limits. CUE showed 5-6 pus cells, initial ultrasound scan of abdomen showed significant amount of urine in bladder and hence was catheterized. Urine and blood samples for c/s were sent. He was febrile and his sugars were on high levels hence started with iv fluids, antipyretics, antibiotics, insulin and other supportive care. On careful history patient has complain of constipation prior to retention of urine.

A per rectal examination was done which revealed tender prostate with positive fluctuation sign. Ultrasonography of abdomen was normal, transrectal ultrasound was done which showed prostatic abscess involving left lobe measuring 3.8 cm (Figure 1).. Surgical opinion was taken and was advised to continue conservative

treatment with follow up scan later. Antibiotic was upgraded to piperacillin/Tazobactam. He was hospitalized until his leukocytosis was normalized and been free of fever for 2 days. He improved symptomatically, follow up transrectal USG showed diminishing abscess size. Urine and blood cultures were sterile. Foleys catheter was removed and there was no discomfort for passing urine. He was discharged on oral antibiotics and insulin to follow up in OPD later.

Figure 1: Transrectal Ultrasound Showing Prostatic Abscess

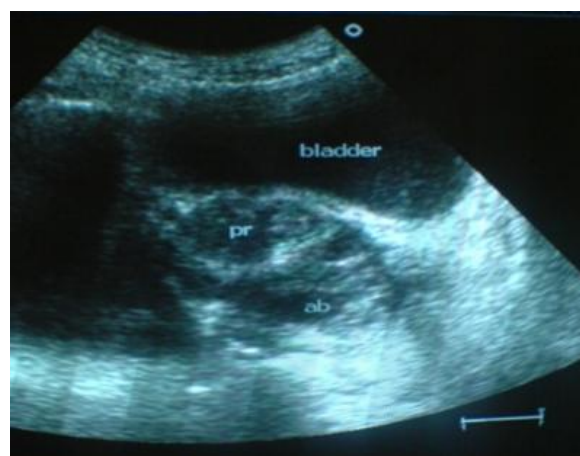
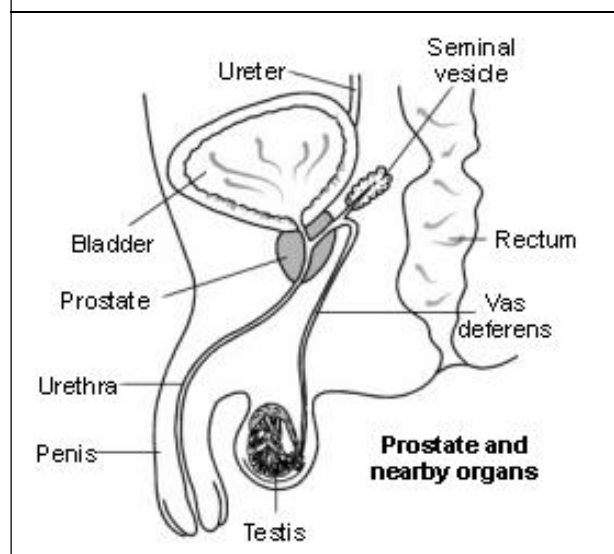


Figure 2: Prostate and Adjacent Structures



## DISCUSSION

Here the patient was rehospitalized due to incomplete evaluation in terms of complete history and physical examination, as it was difficult to correlate between denovo high blood sugars and acute retention of urine. Majority of patients Type2 DM present with osmotic symptoms or nonhealing skin infections, we have seen rare presentation of Type2 DM already reported like Acute MI, Stroke, Ketoacidosis, Erectile dysfunction.

Higher frequency of infection in DM is caused due to reduced response of T cells, damage to neutrophil function, depression of Humoral immunity, but occurrence of prostatic abscess nowadays is very rare. The differential diagnosis between acute prostatitis and prostatic abscess has always been difficult. The distinguishing palpatory finding of a tender, fluctuant prostate on rectal examination has not been a constant occurrence. Recent imaging methods such as TRUS (trans-rectal ultrasound) have been suggested as a noninvasive technique very helpful for the diagnosis of pathological conditions of the prostate. The sonographic pattern of prostatic abscess is characteristic and can be easily differentiated from other glandular lesions. While it is generally accepted that surgical drainage is most important in the treatment of a prostatic abscess, the exact method of drainage remains controversial. USG guidance is preferred to surgery because of its lower risk of complications. Trans-rectal USG also makes it possible to follow up abscesses that were not treated with drainage or puncture but with antibiotic therapy alone.

Here in our case as the abscess size was small and there was easy availability of transrectal

USG, patient was treated conservatively with broad spectrum antibiotics successfully with follow-up scans. As the HbA1c was high at the time of presentation, he was initiated on premixed insulin for better glycemic control for Improving immune status and faster healing of abscess.

## CONCLUSION

In conclusion, we present denovo type 2 diabetic who presented with urinary retention contrary to classical symptoms of osmotic symptoms secondary to prostatic abscess, which required appropriate antibiotic therapy according to urine culture and sensitivity with clinical improvement. TRUS was important in achieving diagnosis and was cost-effective, non invasive and helpful for monitoring the size of abscess. In conclusion small prostatic abscess can be managed conservatively with monitoring of abscess size with complete resolution which we have seen in our patient.

## REFERENCES

1. Chitty K (1957), *Prostatic abscess. Br J Surg*, Vol. 44, pp. 599-601.
2. Cytron S, Weinberger M, Pitlik S D and Servadio C (1988), "Value of transrectal ultrasonography for diagnosis and treatment of prostatic abscess", *Urology*, Vol. 32, pp. 454-58.
3. Dajani A and O'Flynn J D (1968), "Prostatic abscess. A report of 25 cases", *Br J Urol* ., Vol. 40, pp. 736-39.
4. Jacobson J D and Krist E (1993), "Prostatic abscess: A review of literature and presentation of 5 cases", *Scand J Urol Nephrol* , Vol. 27, pp. 281-84.
5. Lee F Jr, Lee F, Solomon M H, Staub W H

- and McLeary R D (1986), "Sonographic demonstration of prostatic abscess", *J Ultrasound Med*, Vol. 5, pp. 101-02.
6. Meares E M Jr (1986), "Prostatic abscess", *J Urol*, Vol. 136, pp. 1281-84.
7. Trapnell J and Roberts M (1987), "Prostatic abscess", *Br J Surg*, Vol. 57, pp. 565-69.
8. Trauzzi S J, Kay C J, Kaufman D G and Lowe F C (1994), "Management of prostatic abscess in patients with human immunodeficiency syndrome", *Urology*, Vol. 43, pp. 629-33.