

ISSN 2278 - 5221

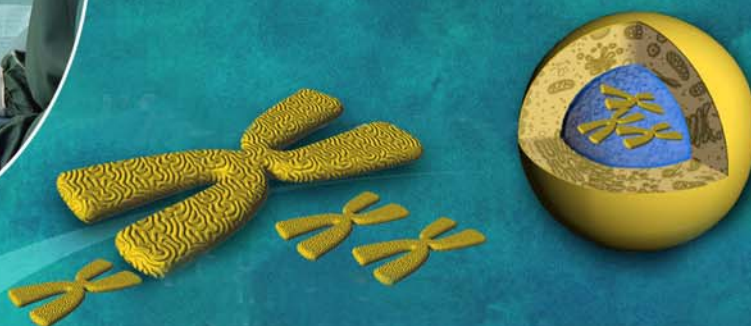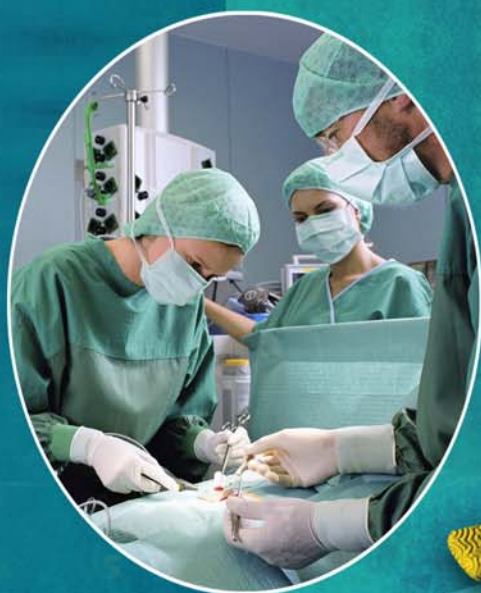Vol. 3, No. 4, October 2014



International Journal of

Pharma Medicine and Biological Sciences

IJPMBS



WWW.IJPMBS.COM

editorijpmbs@gmail.com or editor@ijpmbs.com



Case Report

CHRONIC BUDD CHIARI SYNDROME WITH PROBABLE ETIOLOGY OF OBSTRUCTION BEING A MEMBRANOUS OCCLUSION OF VENA CAVA (MOVC) WITH SECONDARY CHRONIC LIVER DISEASE (NCPF) LEADING TO PORTAL HYPERTENSION: A CASE REPORT

Faraz Farishta^{1*}, Sanda Mallikarjuna Rao¹, Sneha Sagar Parchuri¹
and Mohammed Salman Hadi¹

*Corresponding Author: **Faraz Farishta** ✉ drfarazfarishta@gmail.com

A 25 years old female came with complains of fever since one week and abdominal distension since 5 days . Patient took antimalarial treatment for *Plasmodium falciparum* 6 months back. On examination Mild Hepatomegaly, Moderate Splenomegaly. Patient was investigated with CBP- Hb – 9 gm/dl, WBC – 3,800 / mm³ Platelet count – 60 000 /m³ Malarial antigen test – positive for *Plasmodium vivax*, LFT - Normal, USG Abdomen : Mild Hepatomegaly with Altered Echotexture, Splenomegaly and Minimal Ascites Portal Hypertension : Upper GI Endoscopy : Grade 1 and 2 varicies present. Contrast mri angiography with splenoportal and ivc venography- Chronic Budd Chiari Syndrome with splenomegaly - Secondary Chronic Liver Disease, Minimal Ascites. Thrombophilic profile was Normal. Liver biopsy :Widened portal tracts with peri portal fibrosis- suggestive of Non cirrhotic portal fibrosis. Pateint was treated with Antimalarial and on line of Chronic liver disease.

Keywords: Budd chiari syndrome, Etiology, MOVC, Hypertension

CASE DISCUSSION

A 25 years old female resident of Medak came with complains of fever since one week and abdominal distension since 5 days. Fever started 1 week back, Insidious onset, High grade, Intermittent, with spikes of fever at regular

intervals, Associated with chills and rigors, No h/o sore throat / cold / cough / chest pain on inspiration /breathlessness, No h/o headache / altered sensorium, No h/o burning micturition / hematuria / loin pain, No h/o rash / joint pains, No h/o of localized abscess on the body, No h/o

¹ Mediciti institute of Medical sciences, Ghanpur, Medchal Mandal, Hyderabad, Telangana 501401.

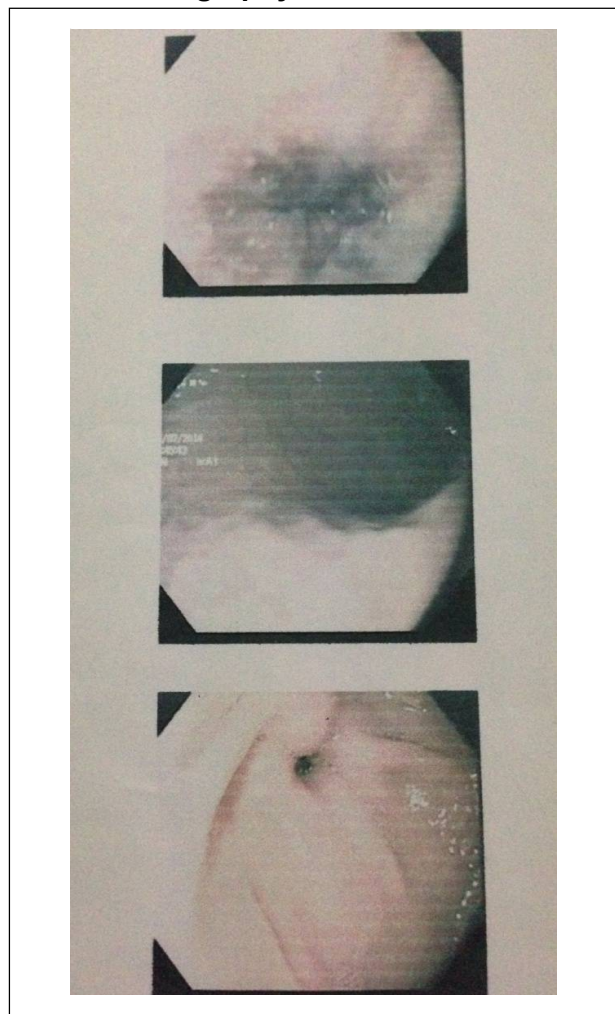
recent travel / transfusion. Patient also complained of Abdominal distension since 5 days, Insidious onset, Progressive, Dull aching, non radiating pain on the right side of upper abdomen, No c/o vomiting / diarrhea ,No c/o yellowish discoloration of eyes, No c/o coffee ground vomitus/frank blood / dark tarry stools/ Constipation/Yellowish discoloration of eyes, No h/o pedal edema, facial puffiness , generalized swelling of the body, No h/o chest pain, breathlessness, palpitations, syncope, No h/o decreased urine output, burning micturition, hematuria or loin pain. Patient had similar complaints of fever with abdominal distension associated with yellowish discoloration of eyes 6 months back, was diagnosed with Falciparum malaria, took antimalarial treatment, following which fever subsided, but abdominal distension resolved only partially, current presentation, the distension aggravated since 5 days. Not k/c/o hypertension, diabetes, asthma, epilepsy, tuberculosis, CAD, Stroke. Patient is married for 2 years, no children. Nonsmoker, Non Alcoholic. Patient took antimalarial treatment for falciparum malaria 6 months back. No h/o herbal medication intake, No h/o surgeries in the past .Patient had spontaneous abortion of her first pregnancy in the first trimester 1 year back, Reason for Abortion not Known.

On examination patient is Thin built , poorly nourished, BMI – 16, Pallor present, Pulse – 105/ m , regular, BP – 110/70 mm Hg, On examination of Respiratory system- Normal vesicular breath sounds heard in all lung fields. On examination of CVS-S₁S₂ heard, no murmurs. On Neurological examination-No focal Neurological deficit found. On abdominal examination- Localised distension of Upper abdomen seen, Tenderness in right hypochondrium, Mild

hepatomegaly – 2 cm below the right costal margin, consistency firm, Moderate Splenomegaly – 5 cm below the left costal margin, No other mass palpable. No shifting dullness.

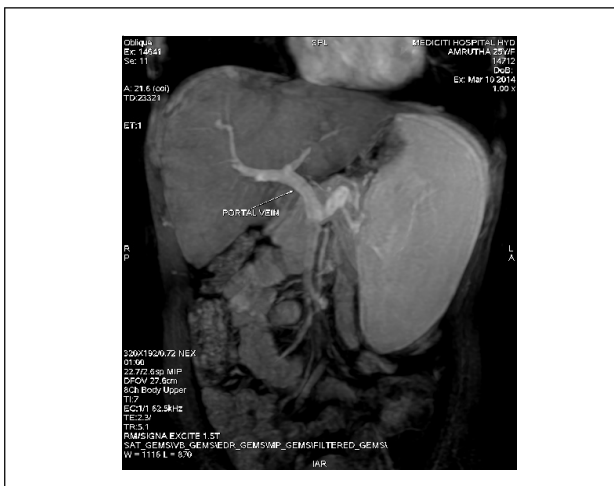
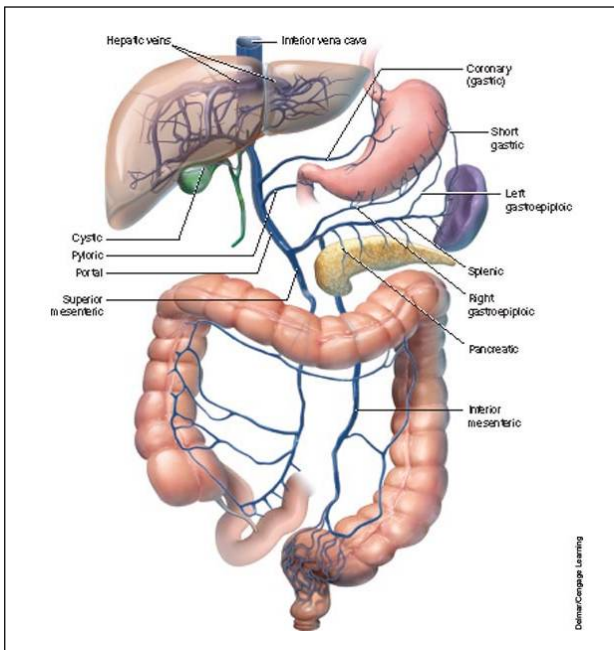
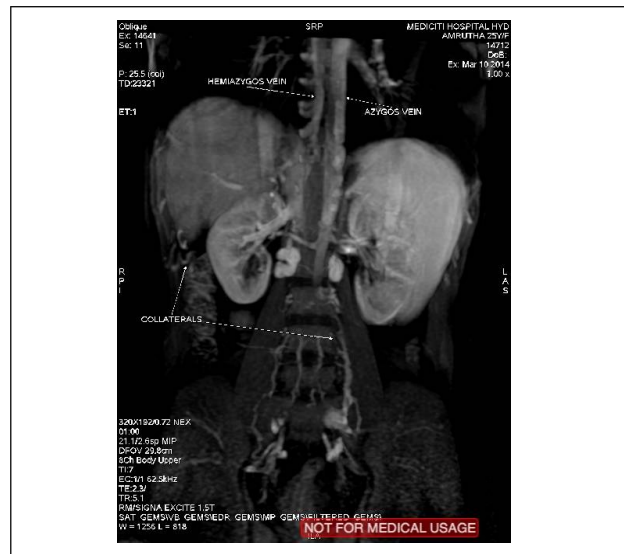
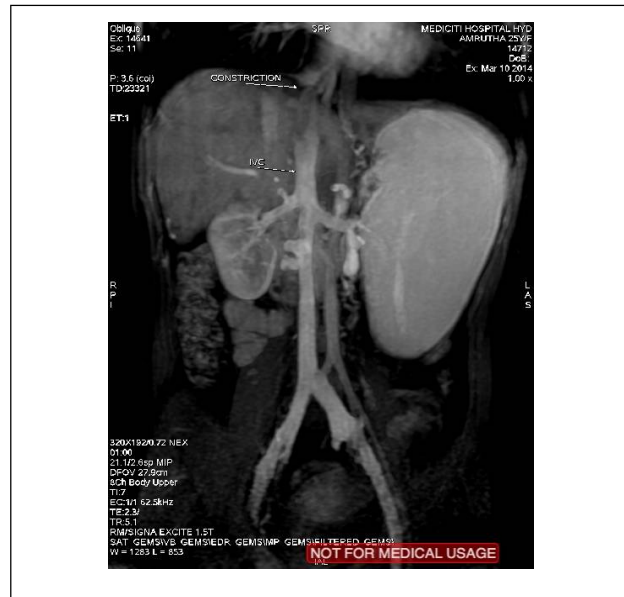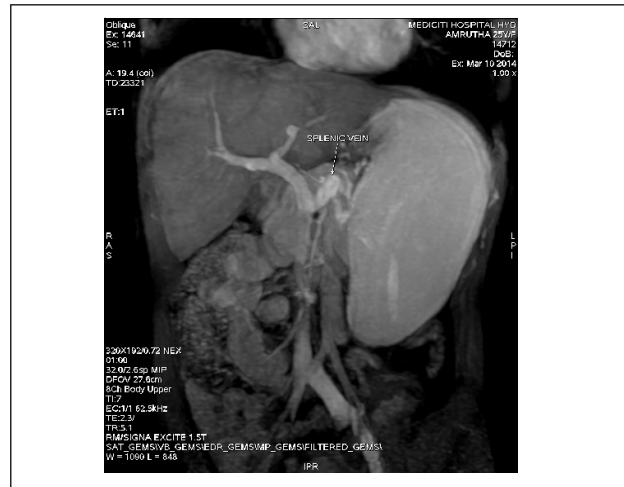Patient was investigated with CBP- Hb – 9 gm/ dl, WBC – 3,800 / mm³ Platelet count – 60 ,00 / mm³ Malarial antigen test – positive for Vivax malaria, LFT - Normal VIRAL MARKERS : NEGATIVE Sr. creatinine – 0.9 mg/dl., Electrolytes – Normal., USG Abdomen : Mild Hepatomegaly With Altered Echotexture, Splenomegaly and Minimal Ascites Portal Hypertension : Upper GI Endoscopy : Grade 1 and 2 varicies present

Contrast MRI angiography with splenoportal and IVC venography: Focal constriction of the



suprahepatic IVC above the confluence with hepatic veins associated with extensive intrahepatic cork screw collaterals, subphrenic, pericapsular, lumbar and vertebral venous collaterals diverting the flow into the azygos and hemiazygos veins – Chronic Budd Chiari Syndrome. Mild irregularity in the outline of the liver with splenomegaly - Secondary Chronic Liver Disease, Minimal Ascites, normal portal circulation.

Liver biopsy : Widened portal tracts with peri portal fibrosis- suggestive of Non cirrhotic portal





International Journal of Pharma Medicine and Biological Sciences

Hyderabad, INDIA. Ph: +91-09441351700, 09059645577

E-mail: editorijpmbs@gmail.com or editor@ijpmbs.com

Website: www.ijpmbs.com

